

Reprinted from

UROLOGY



This article has been published online prior to it being assigned to a volume and issue of the journal. It is available to order and would be printed with a DOI (<http://dx.doi.org/10.1016/j.urology.2012.06.048>) as its reference. The DOI can and should be used in place of the absent volume, issue, and page numbers to cite this article.

Efficacy of BloodSTOP iX, Surgicel, and Gelfoam in Rat Models of Active Bleeding From Partial Nephrectomy and Aortic Needle Injury

Ludovic Ferretti, Xuefeng Qiu, Jacqueline Villalta, and Guiting Lin

No responsibility is assumed by Elsevier, its licensors or associates for any injury and/or damage to persons or property as a matter of products liability, negligence or otherwise, or from any use or operation of any methods, products, instructions, or ideas contained in the material herein. Because of rapid advances in the medical sciences, in particular, independent verification of diagnoses and drug dosages should be made.

OFFICIAL JOURNAL OF THE SOCIÉTÉ INTERNATIONALE D'UROLOGIE



Efficacy of BloodSTOP iX, Surgicel, and Gelfoam in Rat Models of Active Bleeding From Partial Nephrectomy and Aortic Needle Injury

Ludovic Ferretti, Xuefeng Qiu, Jacqueline Villalta, and Guiting Lin

OBJECTIVE	To compare the bleeding time using 3 different hemostatic agents in a rat model of partial nephrectomy and aortic needle injury.
METHODS	Bilateral partial nephrectomy was performed in 20 rats with a total bleeding surface of 1.5 cm ² without vascular clamping. Surgicel (n = 10) or BloodSTOP iX (n = 10) matrix was applied on each kidney cut surface. Finger pressure was applied to the parenchyma with transparent plastic bubble wrap to allow for visualization of the site and monitor the bleeding time. Pressure was applied until the bleeding stopped and then released to assess the presence of active bleeding for 5 minutes. An additional 24 rats underwent aortic trauma with a 25-gauge needle puncture, and the efficacy of the topical hemostatic agents were compared among Gelfoam (n = 8), Surgicel (n = 8), and BloodSTOP iX (n = 8).
RESULTS	After partial nephrectomy, the mean bleeding time with BloodSTOP iX and Surgicel treatment was 83.70 ± 13.73 seconds and 168.8 ± 19.41 seconds, respectively, a statistically significant difference (P = .002). After aortic injury, the mean bleeding time was 157.5 ± 31.44 seconds, 187.5 ± 23.20 seconds, and 66.00 ± 13.74 seconds in the Gelfoam, Surgicel, and BloodSTOP iX groups, respectively, which was statistically significant (P = .004).
CONCLUSION	The BloodSTOP iX hemostatic surgical matrix was more effective in reducing the bleeding time than Surgicel in a rat model of partial nephrectomy. Similarly, in an aortic needle injury model, BloodSTOP iX achieved hemostasis faster than Gelfoam or Surgicel. UROLOGY xx: xxx, xxxx. © 2012 Elsevier Inc.

This article is valid for posting until 09/17/2013.

Electronic Distribution Only

Owing to the limited efficacy of conventional hemostatic techniques (eg, pressure, ligature, and cautery), various topical hemostatic agents have been developed to achieve renal parenchymal hemostasis in renal surgery (eg, nephron-sparing procedures, laparoscopic renal surgery, and repair of renal trauma). To date, fibrin or matrix tissue sealants and synthetic glues, such as oxidized cellulose (Surgicel, Ethicon, New Brunswick, NJ), have been the most effective topical hemostatic agents.^{1,2} Recently, the French National Authority for Health recommended the use of topical hemostatic matrix as a complementary measure to the standard technique (suturing of vessels in the case of nephron-sparing nephrectomy).³⁻⁵ However, no recent

comparison data are available among the different materials to guide the surgeon in the clinical choice of topical hemostatic agent.⁵ BloodSTOP iX (Life Science Plus, Mountain View, CA) is an etherized and oxidized regenerated cellulose matrix that achieves hemostasis by activating the intrinsic coagulation pathway. This material is fully bioresorbable and biocompatible. Few data were found in published studies; therefore, we compared the use of Surgicel, Gelfoam (Baxter, Deerfield, IL), and BloodSTOP iX as the primary technique for hemostasis in a rat model of partial nephrectomy and aortic injury.

MATERIAL AND METHODS

Animals and Experimental Procedures

A total of 44 healthy Sprague-Dawley male rats (age 8 weeks) were obtained from Charles River Laboratories (Wilmington, MA). The University of California, San Francisco, institutional animal care and use committee approved all animal care, treatments, and procedures. The rats were housed for 7 days before the experiments with a 12-hour dark/light cycle. Free access to water and food was allowed. The rats were randomized into

Financial Disclosure: The authors declare that they have no relevant financial interests.

From the Knutpe Molecular Urology Laboratory, University of California, San Francisco, School of Medicine, San Francisco, CA; and University Hospital Pellegrin, Bordeaux, France

Reprint requests: Guiting Lin, M.D., Ph.D., Department of Urology, University of California, San Francisco, School of Medicine, San Francisco, CA 94143-0738.

E-mail: glin@urology.ucsf.edu

Submitted: March 12, 2012, accepted (with revisions): June 27, 2012

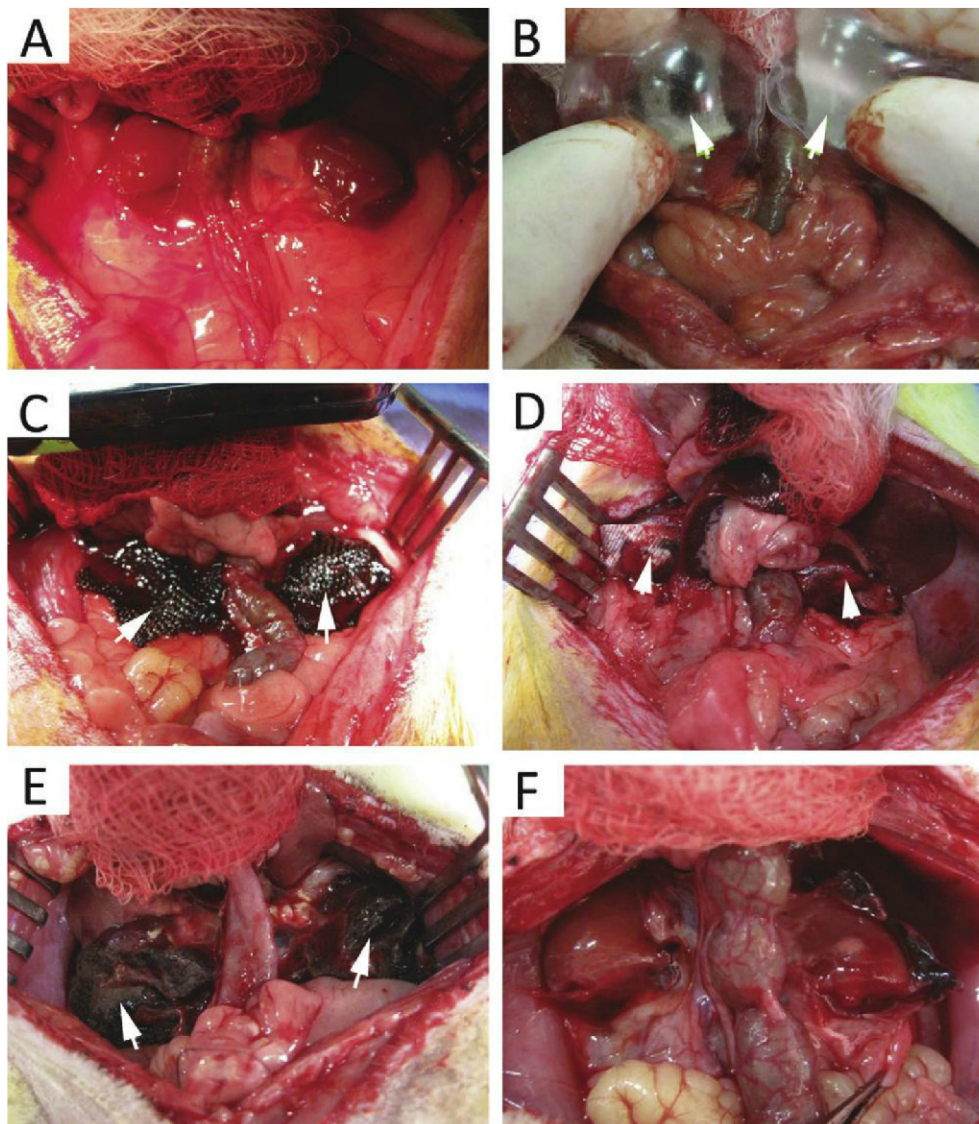


Figure 1. (A) Bilateral lower pole partial nephrectomy. (B) After applying hemostatic matrix to partial nephrectomy wound, plastic package bubble wrap (arrows) was used to apply pressure and observe hemostasis. (C) Surgicel saturated with blood after hemostasis was obtained (arrows). (D) BloodSTOP iX matrix partially stained with blood when hemostasis was achieved (arrows). (E) Thick layer of residual Surgicel matrix (arrows) covering renal wound at 30 days. (F) BloodSTOP iX matrix not detectable at 30 days.

2 groups of 10 rats. Surgicel (Sk) was used in 1 group and BloodSTOP iX (Bk) was used for 1 group. Anesthesia was initiated and maintained by a 3% inhalation of isoflurane, followed by a 0.01-mg/kg injection of buprenorphine. The rats were placed on a heating pad, and antibiotic prophylaxis with enrofloxacin was administered. The rats were shaved on the ventral abdomen, and the skin was prepared with iodized polyvidone. Through a midline laparotomy, bilateral partial lower pole nephrectomies were performed in every rat, allowing a total bleeding surface area of 1.5 cm² (Fig. 1A). The removed kidney fragments were weighed to assess the reproducibility of the partial nephrectomy model. Four layers of Surgicel (Fig. 1C) and two layers of BloodSTOP iX (Fig. 1D) were used by folding the sheet from the package. The topical matrix was applied under digital pressure with transparent plastic bubble wrap, allowing visual monitoring of the bleeding time (Fig. 1B). Digital pressure was applied for 30 seconds and then removed every 10 seconds to assess the achievement of primary hemo-

stasis. When hemostasis was achieved, the plastic bubble wrap was removed, and the surgical site was observed continuously for 5 minutes to detect any rebleeding. In the case of rebleeding, another layer of matrix was used, digital pressure was applied, and timing continued until the bleeding had stopped again. Once all bleeding had stopped, the laparotomy incision was closed in 2 layers. Each rat was observed for 6 hours before being returned to the cage. One half of the rats in each group were killed at 7 days and the remainder at 30 days after the procedure. The abdomen was reopened, and the presence or absence of residual hemostatic matrix adhering to the renal wound was assessed for each rat. The kidneys were then harvested for histologic analysis.

In the aortic injury model, 24 rats were randomized to 3 groups of 8 rats (Gelfoam [Ga], Surgicel [Sa], and BloodSTOP iX [Ba] groups) and underwent midline laparotomy similar to the technique described for nephrectomy. After exposure of the abdominal aorta, a 25-gauge needle was inserted into the aorta

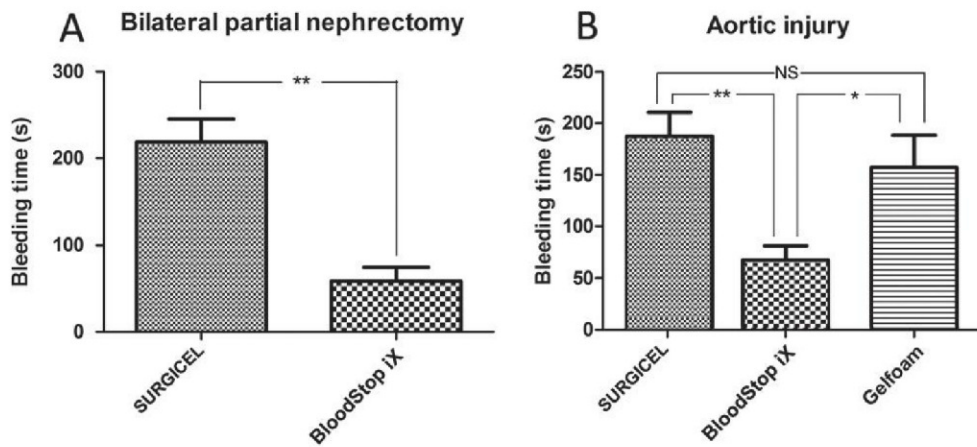


Figure 2. (A) Mean bleeding time of kidneys undergoing partial nephrectomy treated with BloodSTOP iX was much shorter than that of those treated with Surgicel ($P = .002$). **(B)** In aortic injury model, mean bleeding time of rats treated with BloodSTOP iX was significantly less than that of those treated with Surgicel or Gelfoam ($P = .004$).

and then removed, causing severe arterial bleeding. Gelfoam, Surgicel, and BloodSTOP iX were applied in the Ga, Sa, and Ba groups, respectively. The bleeding time was monitored the same as for the partial nephrectomy model. The rats were humanly killed with pentobarbital after a hemostasis observation period of 5 minutes.

Histologic Study

The specimens were fixed for 4 hours with cold 2% formaldehyde and 0.002% picric acid in 0.1 M phosphate buffer, followed by overnight immersion in buffered solution containing 30% sucrose. The tissues were frozen in Optimum Cutting temperature compound (Sakura Finetek, Torrance, CA), and stored at -80°C until use. The sections were cut to $5\ \mu\text{m}$, adhered to charged slides, and air dried for 5 minutes before staining.

Masson's trichrome, hematoxylin-eosin staining, and immunohistochemistry were performed according to previously described protocols.^{6,7} The primary antibodies included mouse anti-CD3 and mouse anti-CD45 (1:500 and 1:200, respectively; Abcam, Cambridge, MA). The staining was performed with the avidin-biotin peroxidase method using the Vectastain Elite ABC kit (Vector Laboratories, Burlingame, CA) with 3,3'-diaminobenzidine as the chromogen.

Statistical Analysis

The primary endpoint was the difference in bleeding time between the 2 groups, Sk and Bk. The mean bleeding time, excised renal parenchyma weight, and adherence of the hemostatic matrix to the renal parenchyma were compared between the 2 groups using a 2-tailed Mann-Whitney U test. In the aortic injury study, 1-way analysis of variance followed by the Bonferroni post hoc test was performed. The results are presented as the mean \pm standard error of mean for the bleeding time and the resected kidney parenchyma weight. $P < .05$ was considered statistically significant. The matrix thickness was compared at 30 days using a t test. All statistical analyses were performed with Prism, version 5.0 (GraphPad Software, La Jolla, CA).

RESULTS

Assessment of Bilateral Partial Nephrectomy Reproducibility

All kidney fragments were weighed and compared between the 2 groups. In the Sk and Bk groups, the mean weight was $0.9210 \pm 0.04542\ \text{g}$ and $0.9150 \pm 0.09496\ \text{g}$, respectively. No statistically significant difference was found between the 2 groups ($P = .9$).

Bleeding Time Comparison

Bilateral Partial Nephrectomy. The mean bleeding time was 83.70 ± 13.73 seconds ($n = 20$) in the Bk group and 168.8 ± 19.41 seconds ($n = 20$) in the Sk group, and the difference was statistically significant ($P = .002$; Fig. 2A). In the Bk group, 2 rats died 6 hours after surgery from active secondary bleeding, and 2 rats died the day after surgery without any evidence of bleeding but with the presence of a large hematoma. In the Sk group, 2 rats died; 1 died 6 hours after surgery from rebleeding and 1 died 10 days later of intestinal obstruction.

Aortic Injury Model. All aortic injuries achieved complete hemostasis with application of the hemostatic agent. The mean bleeding time was 66.00 ± 13.74 seconds in the Ba group, 187.5 ± 23.20 seconds in the Sa group, and 157.5 ± 31.44 seconds in the Ga group. One-way analysis of variance revealed a statistically significant difference ($P = .004$) among the 3 groups. The Bonferroni post hoc test demonstrated a significant difference between the Ba and Ga groups and Ba and Sa groups but not between the Ga and Sa groups (Fig. 2B).

T- and B-Cell Infiltration

A mild degree of infiltration of the T (CD3) and B (CD45) cells into the hemostatic matrix was noted. Few inflammatory cells were seen within the renal parenchymal tissue. Therefore, this likely represented a foreign body reaction, not a true immunologic response (Fig. 3).

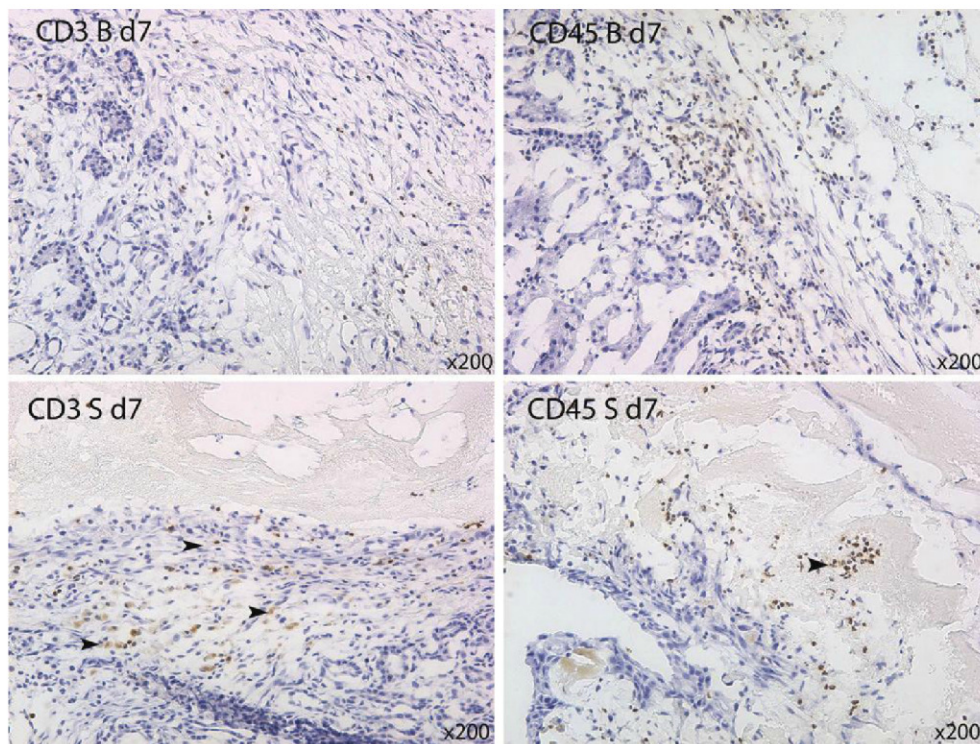


Figure 3. Infiltration of T cells (CD3) and B cells (CD45) of hemostatic matrix (**Upper**) BloodSTOP iX and (**Lower**) Surgicel.

Retention of Hemostatic Matrix

In the Surgicel group, a thick layer of hemostatic matrix covered the renal wound surface at both 7 and 30 days. In the BloodSTOP iX group, only a thin layer of matrix was seen at 7 days, and the matrix was almost invisible at 30 days. When measured under microscopy, a significant difference was seen in the thickness of the attached matrix between the Surgicel and BloodSTOP iX group ($P < .05$; Fig. 4).

COMMENT

Topical hemostatic matrices are effective complementary hemostatic agents in human surgery, as recently recommended.⁸ In renal nephron-sparing surgery, the ischemia time and blood loss are important issues.^{4,9-13} The warm ischemia time correlates with the tumor size and achievement of hemostasis.^{2,14} Therefore, better hemostatic methods are needed to shorten the bleeding time and improve the renal functional outcomes. In laparoscopic or robotic partial nephrectomy, biologic or synthetic fibrin glue is used, alone or combined with other hemostatic agents to achieve renal parenchymal hemostasis.¹ The main mechanism of action of fibrin glue is to trigger the intrinsic pathway of the coagulation cascade with the help of thrombin, found in actively bleeding tissue.⁵ To our knowledge, the present study is the first experimental comparison between the 2 oxidized cellulose matrices, Surgicel and BloodSTOP iX. The experimental results indicated that a shorter bleeding time was achieved with BloodSTOP iX than with Surgicel. BloodSTOP iX, when

hydrolyzed by water, becomes a gel that can adhere to the bleeding surface and normal parenchyma. These properties allow sealing of the bleeding surface during partial nephrectomy. This could explain the faster achievement of hemostasis compared with Surgicel, in which the blood will form a clot that is trapped in the mesh but without sealing of the bleeding surface. This is the reason we used 4 layers of Surgicel versus 2 layers of BloodSTOP, which was the minimal amount of matrix required to stop the arterial bleeding from kidney parenchyma.

A major limit of the present study was the absence of a control group, which would have been partial nephrectomy without any agent and the control of bleeding only by digital pressure. In our pilot study, hemostasis of the kidney parenchyma was not possible with digital pressure alone; therefore, no control group was used in the present study.

Although BloodSTOP iX was more effective in decreasing the coagulation time than Surgicel, its use can be difficult in cases of excessive bleeding. The hemostatic sheets need to be handled with dry gloves and dry instruments. Any contact with blood or with water will trigger hydrolysis of the cellulose monomer, making the sheet adherent to any material in the operating field. This agent should not be used as the primary hemostatic technique on large bleeding surfaces, because the sheets of matrix are difficult to work with when in contact with fluid. Nevertheless, it might help secure hemostasis once excess bleeding has been controlled using sponges and

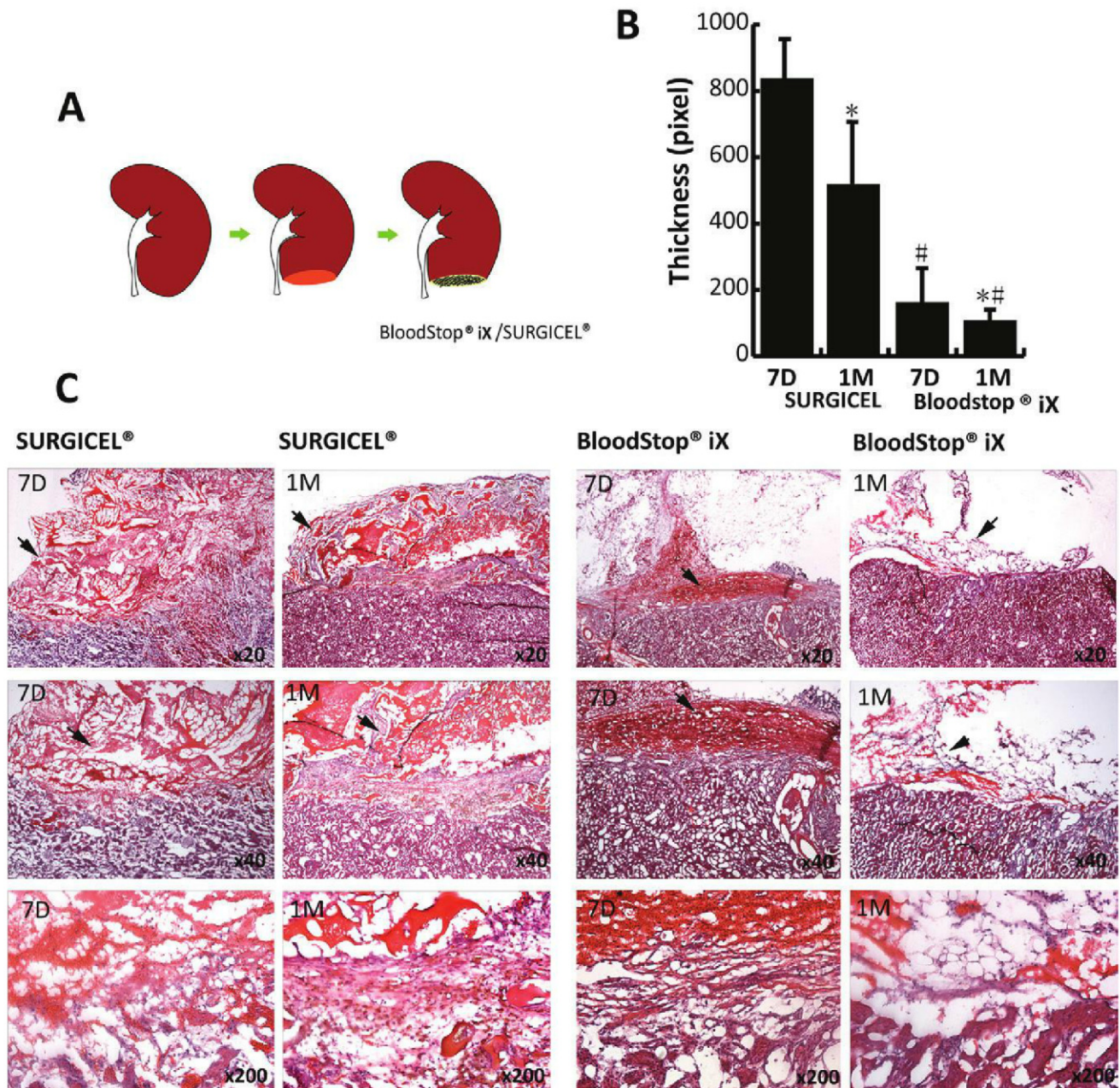


Figure 4. (A) Lower pole partial nephrectomy. **(B)** Thickness of residual matrix attached to renal wound at 7 and 30 days. **(C)** Histologic view of residual matrix attached to wounds at 7 and 30 days at different magnifications ($\times 20$ - 200). Arrows depict residual matrix.

suction. In the present study, slight arterial bleeding could be stopped by the application of a topical matrix, without clamping of the hilum. However, if excessive abdominal fluid is present after hemostasis is achieved, the BloodSTOP iX matrix could dissolve too quickly, resulting in postoperative bleeding, such as was seen in 2 rats in our experiment. Therefore, in human surgery, we strongly recommend that arterial bleeding vessels be ligated with suture before applying the hemostatic agent to the bleeding surface and that BloodSTOP iX should be used as a secondary form of hemostasis. One of the limitations of the present study was that the application of a topical hemostatic agent without any suturing does not represent the normal situation for partial nephrec-

tomy in humans. In most cases, no additional hemostasis was required after suture ligating all visible bleeding vessels in human partial nephrectomy.

Postoperative surveillance after partial nephrectomy for renal tumor includes serial contrast enhanced computed tomography to rule out the presence of local recurrence, metastatic progression, or the presence of a contralateral metachronous tumor. The presence of persistent hemostatic matrix 6 months postoperatively could lead to a misinterpretation of the postoperative computed tomography scan, mimicking tumor recurrence or an abscess at the tumor resection bed.¹⁵ Moreover, these postoperative changes resulting from the persistent presence of hemostatic matrices could take up contrast and

lead to unnecessary biopsy or completion nephrectomy. Because BloodSTOP iX is hydrolyzed and absorbed faster, it might have the additional advantage of improved postoperative radiologic imaging when used in cancer surgery.

Efficient and effective hemostatic matrices are necessary on the battlefield to stop acute hemorrhage and allow soldiers to be safely transported to a field hospital for surgery. In the present study, BloodSTOP iX demonstrated its superiority to Gelfoam and Surgicel in achieving hemostasis faster. This property could be very useful in preventing excessive bleeding and decreasing immediate mortality. Although 1 study of a femoral artery injury model in swine did not show any difference in the rate of rebleeding and overall survival between several topical hemostatic matrices, including BloodSTOP iX,¹⁶ more studies are warranted to determine the best hemostatic agent for treating battlefield injuries.

CONCLUSIONS

BloodSTOP iX is efficient and safe in achieving renal parenchymal hemostasis without hilar or parenchymal clamping in a partial nephrectomy rat model. The mean bleeding time was dramatically decreased compared with the use of Surgicel. Similarly, in an aortic injury model, BloodSTOP iX achieved hemostasis faster than either Gelfoam or Surgicel. Improvement in the handling of the product to prevent adherence to any moist surface could place this oxidized material as the top choice of topical hemostatic matrix for nephron-sparing surgery.

Acknowledgment. To LifeScience (Mountain View, CA) for donating the experimental materials.

References

- Hong YM, Loughlin KR. The use of hemostatic agents and sealants in urology. *J Urol*. 2006;176:2367-2374.
- Stojkovic I, Savic V, Djokic M, et al. Possibilities and limitations of fibrin glue usage in nephron-sparing surgery: experimental study. *Urol Int*. 2005;74:355-360.
- Sileshi B, Achneck HE, Lawson JH. Management of surgical hemostasis: topical agents. *Vascular*. 2008;16(suppl 1):S22-S28.
- van Dijk JH, Pes PL. Haemostasis in laparoscopic partial nephrectomy: current status. *Minim Invasive Ther Allied Technol*. 2007;16:31-44.
- Dalpiaz O, Neururer R, Bartsch G, et al. Haemostatic sealants in nephron-sparing surgery: what surgeons need to know. *BJU Int*. 2008;102:1502-1508.
- Garcia MM, Fandel TM, Lin G, et al. Treatment of erectile dysfunction in the obese type 2 diabetic ZDF rat with adipose tissue-derived stem cells. *J Sex Med*. 2010;7:89-98.
- Lin G, Wang G, Liu G, et al. Treatment of type 1 diabetes with adipose tissue-derived stem cells expressing pancreatic duodenal homeobox 1. *Stem Cells Dev*. 2009;18:1399-1406.
- Aubourg R, Putzolu J, Bouche S, et al. Surgical hemostatic agents: assessment of drugs and medical devices. *J Vasc Surg*. 2011;148:e405-e408.
- Walters RC, Collins MM, L'Esperance JO. Hemostatic techniques during laparoscopic partial nephrectomy. *Curr Opin Urol*. 2006;16:327-331.
- Yoshikawa Y, Ono Y, Hattori R, et al. Laparoscopic partial nephrectomy for renal tumor: Nagoya experience. *Urology*. 2004;64:259-263.
- Thompson T, Ng CF, Tolley D. Renal parenchymal hemostatic aids: glues and things. *Curr Opin Urol*. 2003;13:209-214.
- Tuthill DD, Bayer V, Gallagher AM, et al. Assessment of topical hemostats in a renal hemorrhage model in heparinized rats. *J Surg Res*. 2001;95:126-132.
- Krishnamurti C, Maglasang P, Rothwell SW. Reduction of blood loss by infusion of human platelets in a rabbit kidney injury model. *Transfusion*. 1999;39:967-974.
- Shekarriz B, Stoller ML. The use of fibrin sealant in urology. *J Urol*. 2002;167:1218-1225.
- Farina Perez LA, Delgado C, Dos Santos J. [Oxidized cellulose (Surgicel) mimics an abscess after laparoscopic partial nephrectomy]. *Actas Urol Esp*. 2004;28:54-56.
- Arnaud F, Parreño-Sadalan D, Tomori T, et al. Comparison of 10 hemostatic dressings in a groin transection model in swine. *J Trauma*. 2009;67:848-855.

BloodSTOP iX products are US FDA 510(k) cleared for emergency and therapeutic use in the control of bleeding from the skin and other surface wounds where temporary control of bleeding is required. BloodSTOP iX has European Union Class III CE Mark Certification approval for internal, absorbable use. This study concerns internal, absorbable use, which has not been approved by the US FDA.

LSP supplied the test materials for the study.
This reprint is being disseminated at the expense of LifeSciencePLUS, Inc.



ELSEVIER

email: reprints@elsevier.com

CPC B184460