

Treatment of non-healing Wounds with a Jet Lavage System for Debridement (Jetox).

5/18/2020

Treating non healing wounds in the outpatient setting can be challenging. Removing debris, necrotic tissue, and fibrin from the non-healing wounds to enhance healing can be challenging when performed as bedside procedure (dealing with pain management, equipment, nursing staff etc.).

Foot and ankle infections are one of the most common reason for hospital admissions and among the most devastating and costly complications for patients with diabetes mellitus in the United States and England. It is estimated that more than 5% of all patients with diabetes will have at least one episode of foot ulcer during their life.²¹ Yearly incidence is estimated to be around 2% but reported recurrence rates range between 30% and 40% in the first year. There is also a risk of 40% to sustain a new ulcer after wound healing.

Foot ulceration can lead to a limb or even life-threatening infection. It is estimated that 85% of all amputations in diabetic patients are related to an ulcer and 59% of amputation are performed due to infection.

Preventing formation of ulcers is therefore the primary objective goal when treating diabetic patients. Great effort should be made on patient's education about foot hygiene, proper footwear, specific insoles and regular visual checks by the patient himself and/or healthcare professionals in intervals indicated by the individual risk score (IWGDF).

Once an ulceration has occurred the optimal treatment depends on a multidisciplinary approach that addresses the underlying causes.

The classic objectives in treating foot ulcers are: Offloading the ulcer, a thorough debridement of the infected and nonvital tissue followed by proper antibiotic treatment.

There are several wound debridement types that can be used when considering wound debridement.

1. **Mechanical debridement**- Using surgical equipment. (Scalpels, Ronguers, Currete etc.)
2. **Chemical debridement**- Using different enzymes, gels.
3. **Biological debridement**- Maggots.

4. **Hydro or Ultrasonic debridement** – subtype of mechanical debridement- Using different pressurized liquids (Saline, Prontosane, Octaneline etc.) or ultrasonic liquid waves.

Jetox is a Hydro Jet Lavage wound cleansing and debridement mechanical system. The unique technology creates a jet stream from sterile saline and oxygen with a controlled PSI. The micro drops created by Jetox are 5-100 microns in size and are accelerated to velocities of up to 200 meters per second. This unique system allows the physician to thoroughly remove debris, dead tissue and exudate from the wound while helping to decrease the bacterial load in the wound.

Gil Ganot M.D is an Orthopedic foot and ankle consultant who among his expertise is non healing wounds specialist. Gil Ganot M.D is the head of two big non healing wounds clinics in Israel.

Dr Ganot has been using the Jetox lavage system for the past 4 years treating patients with non-healing wounds.

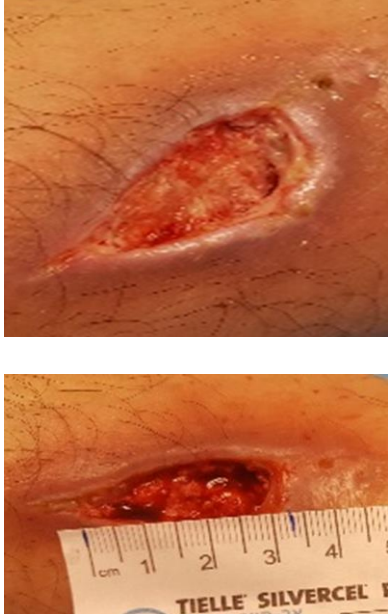


The following cases are examples from Dr Ganot's vast experience using the Jetox Lavage


Conclusion

I found the Jetox solution to be very effective in cleaning and debridement of chronic wounds. Jetox is simple to set up and use and most importantly relatively painless for my patients. As you will read from the three cases below the Jetox solution was quite effective in helping in the healing of these chronic wounds.

Case 1


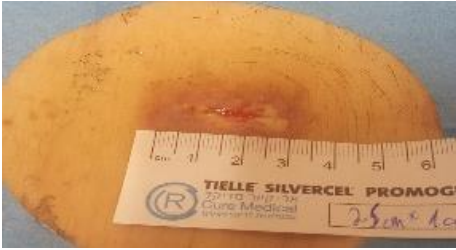


62 years old male who had undergone bypass surgery several months before presenting to the clinic. He had a deep open wound in his shin as a result from the removal of sutures used in his bypass surgery.

Visit Date	Observation	Image
First Visit – 9/5/17	Initial visit. Jetox was used to debride the wound and to remove necrotic and fibrin tissue.	
Second Visit – 9/12/17	Jetox was used to clean and debride the wound.	
Third Visit – 9/19/17	Debridement with Jetox. Removal of fibrin tissue. Notice decrease in wound size and improvement in granulation tissue.	

Visit Date	Observation	Image
Fourth Visit – 10/3/17	Final Jetox debridement. Wound has decreased in size and depth considerably. Good granulation tissue in the base of the wound.	




Case 2


71-year-old male patient with a medical history of diabetes type 2 and atrial fibrillation. The patient presented to the clinic 4 weeks after undergoing spine surgery. He has his sutures removed on 7/2/17. He arrived at the clinic with surgical wound dehiscence and infection.

Visit Date	Observation	Image
First Visit – 8/1/17	Initial visit. Wound was covered with tissue fibrin. Debridement was performed with a scalpel and Jetox.	 <p>A photograph of a surgical wound on a patient's back. The wound is approximately 2.5 cm long and 1.5 cm wide. A ruler is placed below the wound for scale. The wound bed is filled with red, bloody tissue and fibrin.</p>
Second Visit – 8/8/17	Wound size is now 2.5 * 1.5. Debridement was performed with a Jetox to remove fibrin.	 <p>A photograph of the surgical wound after debridement. The wound is now 2.5 cm by 1.5 cm. A ruler is placed below the wound. A piece of yellow dressing is visible, with a label that reads "TIELLE SILVERCEL PROMOG" and "Gore Medical".</p>
Third Visit – 8/15/17	Wound size is now 2 * 1. Debridement was performed with Jetox.	 <p>A photograph of the surgical wound after further debridement. The wound is now 2 cm by 1 cm. A gloved hand is holding a clear plastic tube over the wound.</p>
Fifth Visit – 9/19/17	The wound is healed	 <p>A photograph of the surgical wound after healing. The wound is now a small, healed scar on the patient's back.</p>

Case 3

81-year-old female patient with a medical history of diabetes type 2 presented to the clinic after walking barefoot on a beach. She had pain and a skin lesion on her right plantar foot which was diagnosed as SCC (Squamous Cell Carcinoma). She had undergone removal of the skin lesion and skin grafting. The graft was not incorporated to the surrounding tissue.

Visit Date	Observation	Image
First Visit – 7/18/17	Surgical debridement. Patient is in a lot of pain. The skin graft did not incorporate properly.	
Second Visit – 7/25/17	Surgical debridement. Patient is in visible pain and complained of the high level of pain.	
Third Visit – 8/1/17	Because of the severe patient pain, Jetox is used for debridement.	

Visit Date	Observation	Image
Fourth Visit – 8/8/17	Jetox is used for debridement. Patient describe no pain when using Jetox for wound debridement. Notice the decrease of wound size and depth. Good granulation tissue in the ulcer bed.	
Fifth Visit – 9/5/17	The wound has healed.	

References:

1. Abbott CA, Carrington AL, Ashe H, et al. The northwest diabetes foot care study: incidence of and risk factors for new diabetic foot ulceration in a community patient cohort. *Diabet Med.* 2002;19:377-84.
2. Apelqvist J, Larsson J, Agardh CD. Long-term prognosis for diabetic patients with foot ulcers. *J Intern Med.* 1993;233(6):485-91.
3. Aragón-Sánchez FJ, Cabrera-Galván JJ, Quintana-Marrero Y et al. Outcomes of surgical treatment of diabetic foot osteomyelitis: a series of 185 patients

- with histopathological confirmation of bone involvement. *Diabetologia*. 2008;51(11):1962-70.
4. Bader MS. Diabetic foot infection. *Am Fam Physician*. 2008;78(1):71-9.
 5. Bhatia C, Tiwari AK, Sharma SB et al. Role of Antibiotic Cement Coated Nailing in Infected Nonunion of Tibia. *Malays Orthop J*. 2017;11(1):6-11.
 6. Boyko EJ, Ahroni JH, Cohen V et al. Prediction of diabetic foot ulcer occurrence using commonly available clinical information. *Diabetic Care*. 2006;29:1202-7.
 7. Bus SA; van Netten JJ; Lavery LA et al. WGDF Guidance on the prevention of foot ulcers in at-risk patients with diabetes. *Diabetes Metab Res Rev*. 2016;32:(Suppl. 1)16-24.
 8. Bus SA, Waaijman R, Arts M et al. Effect of custom-made footwear on foot ulcer recurrence in diabetes: a multicenter randomized controlled trial. *Diabetes Care*. 2013;36:4109-4116.
 9. Calvert G, May LA, Theiss S. Use of permanently placed metal expandable cages for vertebral body reconstruction in the surgical treatment of spondylodiscitis. *Orthopedics*. 2014;37(6):536-42.
 10. Chuan F, Tang K, Jiang P et al. Reliability and Validity of the Perfusion, Extent, Depth, Infection and Sensation (PEDIS) Classification System and Score in Patients with Diabetic Foot Ulcer. *PLoS One*. 2015;10(4):0124739.
 11. Kerr M, Rayman G, Jeffcoate WJ. Cost of diabetic foot disease to the National Health Service in England. *Diabet Med*. 2014;31(12):1498-504.

12. Kim JY, Kim TW, Park YE et al. Modified Resection Arthroplasty for Infected Non healing Ulcers with Toe Deformity in Diabetic Patients. *Foot Ankle Int.* 2008 May;29(5):493-7
13. Kimawi AA, Snyder RJ, Cala MA et al. When Traditional Offloading is not an Option, Could an External Fixator be a Solution? A Case Report. *Wounds.* 2017;29(2):46-50.
14. Lavery L, Peters E, Williams J et al. Reevaluating the Way We Classify the Diabetic Foot: Restructuring the diabetic foot risk classification system of the International Working Group on the Diabetic Foot. *Diabetes Care.* 2008;31(1):154-6.
15. Lipsky BA, Berendt AR, Cornia PB et al. 2012 infectious diseases society of america clinical practice guideline for the diagnosis and treatment of diabetic foot infections. *J Am Podiatr Med Assoc.* 2013;103(1):2-7.
16. Monteiro-Soares M, Boyko EJ, Ribeiro J et al. Risk stratification systems for diabetic foot ulcers: a systematic review. *Diabetologia.* 2011;54(5):1190-1199.
17. Mueller MJ, Sinacore DR, Hastings MK et al. Effect of Achilles tendon lengthening on neuropathic plantar ulcers: a randomized clinical trial. *J Bone Joint Surg [Am].* 2003;85-A:1436-45.
18. Örneholm H, Apelqvist J, Larsson J et al. Recurrent and other new foot ulcers after healed plantar forefoot diabetic ulcer. *Wound Repair Regen.* 2017;25(2):309-315