

## Plastic surgeon's testimonial of using BloodSTOP iX to treat large open skinless wound, controlled and accelerated healing

**Ibrahim H Amjad MD, Plastic Surgeon**

**Miami Children's Hospital**

**Miami, FL.**

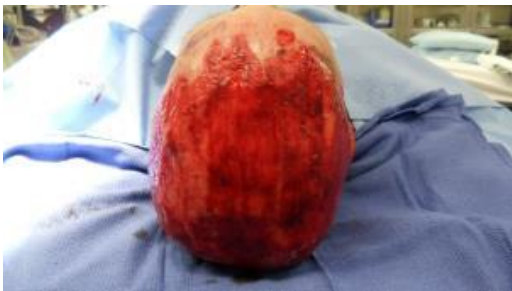A 9 year old female with unknown genetic disorders presented after multiple treatments of open wounds of the scalp, abdomen and leg. Attempts at using Sulfamylon, Aquacel AG, Silvadene, and Gentian Violet yielded no improvement.

The most worrisome component of the patient's care was the weekly cleanings in which the patient bled over 500cc's, requiring transfusion of 2 units of blood at every OR visit.

With the introduction of BloodSTOP iX, wound debridments were able to be done limiting blood loss to <200cc's and only requiring one unit or a partial unit of blood.

With good wound care, decrease of infections secondary to IV antibiotics and improved nutritional status, wounds started healing. Without the use of BloodSTOP iX, any type of debridement and cleaning of these wounds would not have been possible at one OR sitting.

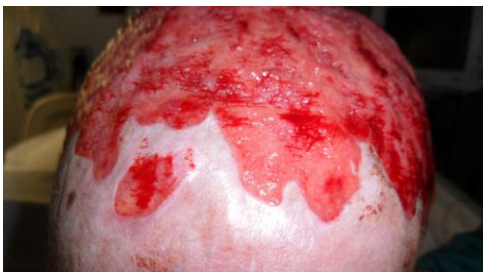To conclude, all prior treatments failed to stop the bleeding for the patient's head, chest and legs. However, her situation was controlled with BloodSTOP iX.



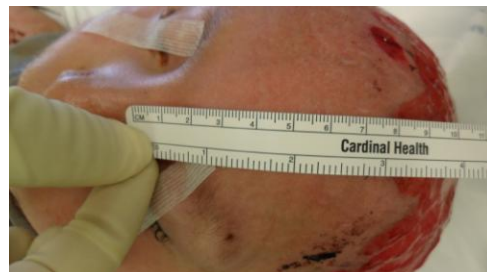She had no scalp after debridement



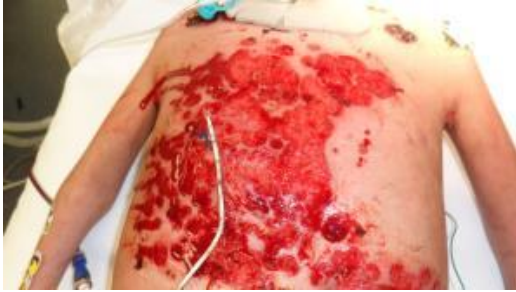Covered with BloodSTOP iX



New tissue grew, healing in process



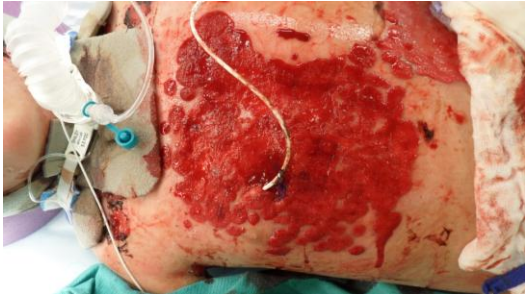
New tissue grew, healing in process



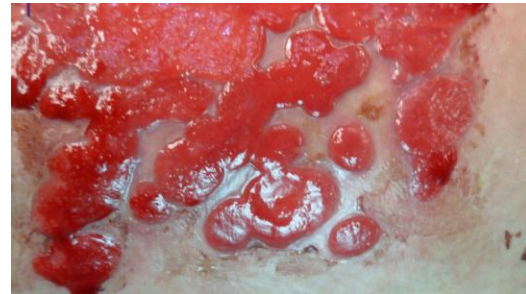
Her chest



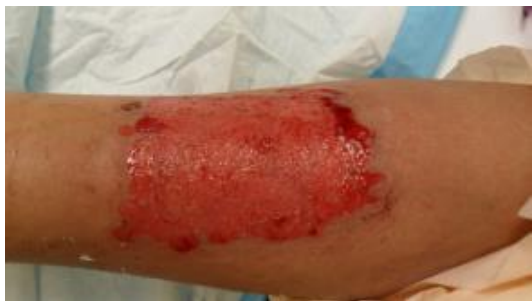Covered with BloodSTOP iX



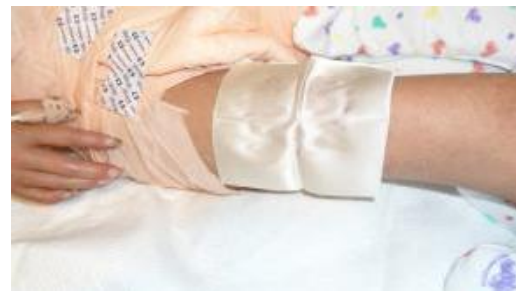New tissue grew, healing in process



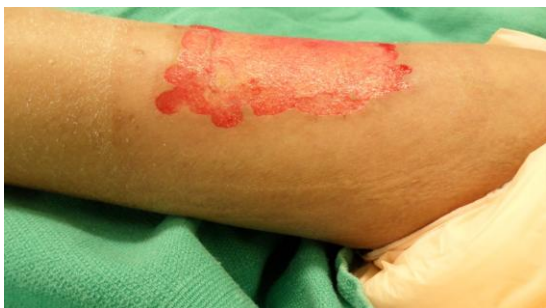New tissue grew, healing in process



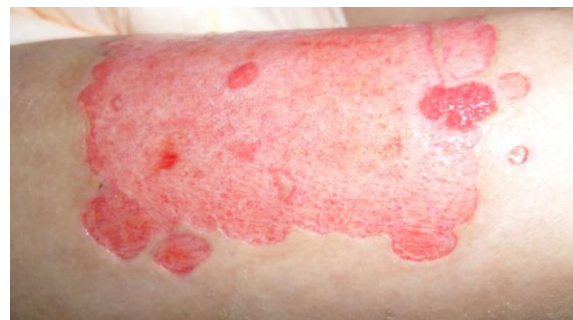Her leg



Covered with BloodSTOP iX



New tissue grew, healing in process



New tissue grew, healing in process